

# Optimizing Volar Tilt Restoration and Plate Position in Distal Radius Fractures

Kristen M. Sochol, MD, MS,\*† Matthew Gluck, MS,\* Joshua McGough, MS,\* Michael Hausman, MD\*

**Purpose** Distal radius fractures are common and often treated surgically with a volar plate. A complication of volar plating includes tendonitis or rupture of the flexor pollicis longus (FPL) tendon. We hypothesize that failure to restore the volar tilt of the distal radius results in increased pressure on the FPL tendon.

**Methods** Ten fresh-frozen cadaveric wrists were assessed for this study. During testing, weights were suspended from the FPL tendon to stimulate muscle contraction. Reproducible fractures were created and fixed via volar plating. The contact force between FPL and the bone or plate edge was measured with a force transducer in 5 surgical conditions. These were assessed to evaluate whether failure to restore the volar tilt increases the pressure with a plate proximal or distal to the watershed line.

**Results** Significant increases in contact forces were observed between the control and both conditions in which volar tilt was not restored, with mean increases of 1.9 N and 3.0 N. A significant increase in the contact force was found when placing the plate distal to the watershed line with a mean increase of 2.03 N comparing the failure to restore volar tilt and after restoring the volar tilt. Significant increases in contact force were also observed between the dorsal plate condition, which failed to restore the volar tilt, and both plate conditions with placement distal to the watershed line, with mean differences of 0.94 N and 1.09 N, respectively.

**Conclusions** Failure to restore the volar tilt in surgically treated distal radius fractures causes increased pressure on the FPL tendon. Plate placement distal to the watershed line also causes increased FPL tendon pressure over the plate edge.

**Clinical relevance** This study demonstrates the importance of restoring the volar tilt of the distal radius in surgically treated distal radius fractures and confirms that plate placement distal to the watershed line will increase pressure on the FPL tendon. (*J Hand Surg Am.* 2022; ■ (■):1.e1-e7. Copyright © 2022 by the American Society for Surgery of the Hand. All rights reserved.)

**Key words** Biomechanical study, distal radius fracture, flexor pollicis longus tendon, volar plate.



**D**ISTAL RADIUS FRACTURES are among the most common injuries in orthopedic practice, accounting for 8% to 15% of all bony injuries

in adults, and upwards of 18% of all fractures in elderly populations.<sup>1,2</sup> Fractures of this type were responsible for up to 1.5% of all emergency

From the \*Icahn School of Medicine at Mount Sinai, New York, NY; and †Department of Orthopedic Surgery, Zucker School of Medicine, Peconic Bay Medical Center-Northwell Health, Riverhead, NY.

Received for publication May 2, 2020; accepted in revised form May 18, 2022.

No benefits in any form have been received or will be received related directly or indirectly to the subject of this article.

**Corresponding author:** Kristen M. Sochol, MD, MS, Department of Orthopedic Surgery, Zucker School of Medicine, Peconic Bay Medical Center-Northwell Health, 1300 Roanoke Avenue, Riverhead, NY 11901; e-mail: ksochol@northwell.edu.

0363-5023/22/ ■ ■ -0001\$36.00/0  
<https://doi.org/10.1016/j.jhssa.2022.05.013>

department visits, with over 640,000 cases reported in the United States in 2001.<sup>3,4</sup> While most of these injuries can be treated non-operatively, more complex fractures may require surgical management. Although various surgical techniques exist, volar plating is the most commonly used strategy.<sup>5–8</sup>

The use of volar plates for the treatment of distal radius fractures has gained wide acceptance since its conception: from 42% of plate-treated fractures in 1999 to 81% in 2007.<sup>9</sup> Volar plating is an alternative to dorsal plate fixation because of concern for extensor tendon rupture and tenosynovitis.<sup>10–12</sup> Additionally, a more rigid implant can be used on the volar aspect of the distal radius, allowing for stronger resistance and lower angular deformity to high loads, making it an appealing option for unstable fractures. This approach has also been shown to provide improved short-term functional outcomes.<sup>13</sup>

However, volar plating has its complications. Irritation, adhesion, laceration, tenosynovitis, and even rupture of the flexor pollicis longus (FPL) tendon may occur.<sup>14–17</sup> Soong et al<sup>18</sup> reported a 4% FPL rupture rate in patients with fractures fixed with a volar plate. As such, efforts should be made to optimize both the surgical and nonsurgical management of this injury.<sup>19</sup>

In 2006, J. Orbay and Touhami<sup>20</sup> described the watershed line of the distal radius. They affirmed that the gliding surface of the flexor tendons would not encounter the volar plate if the implant does not cross or project volar to this distal ridge. This ridge is within 2 mm of the joint line on the ulnar aspect of the distal radius, which is the volar rim of the lunate fossa. The radial aspect of the ridge is 10 to 15 mm proximal to the joint line. However, this presumes that anatomic restoration of palmar tilt has been achieved. If this is not the case, the distal edge of the volar plate may contact or even apply pressure to the tendons even if the plate has been correctly applied proximal to the distal ridge.

The contact force on the FPL of various wrist positions with and without using a volar plate has been previously evaluated. Tanaka et al<sup>21</sup> showed in 7 cadaveric wrists that significant increases in contact force was applied to the flexor tendons, including the FPL, when a volar plate is placed distal to the watershed line for both 1.5 and 3 kg weights at varying degrees of wrist extension.

Other studies have also evaluated plate position as a risk factor for FPL rupture in patients.<sup>22</sup> In fact, Wurtzel et al<sup>23</sup> have shown that loss of anatomic volar tilt, increasing wrist extension, and distal

placement of a volar plate result in increased contact pressure on the FPL tendon.

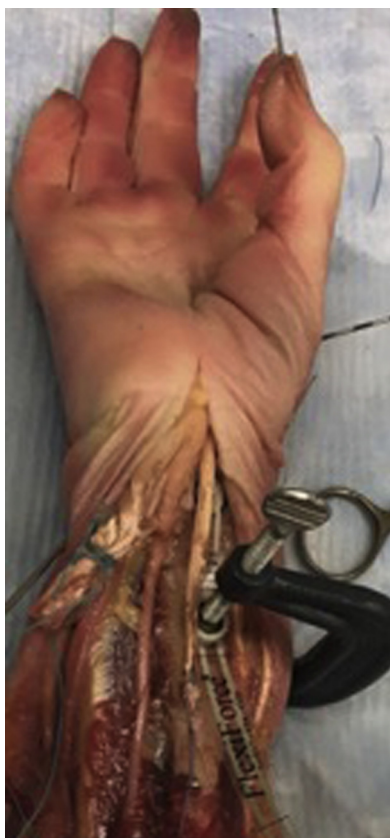We sought to investigate the effect of loss of volar tilt on FPL tendon pressure in conjunction with volar plate placement proximal to or 2 mm distal to the watershed line using the pressure sensor methodology used by Tanaka et al.<sup>21</sup> While several biomechanical studies have assessed plate placement distal or proximal to the watershed line as a potential factor contributing to rupture, there is a paucity of literature investigating the necessity to restore anatomic volar tilt of the distal radius fracture in conjunction with optimal plate placement. This is especially true in an extended wrist position when forces are highest on the FPL tendon.<sup>23</sup> As such, this study seeks to replicate the findings by Wurtzel et al<sup>23</sup> and expand upon them by evaluating not just plate placement, but also restoration of volar tilt as a contributing factor to FPL tendon rupture. We hypothesize that the failure to restore the anatomic volar tilt of the distal radius and the placement of a volar plate distal to the watershed line will result in higher contact forces on the FPL tendon.

## MATERIALS AND METHODS

### Specimen preparation

This study assessed 10 fresh-frozen cadaveric upper extremities (mean age, 70 years; range, 46–89 years). The subjects had no reported history, clinical or radiographic findings of hand, wrist, forearm trauma, or degenerative changes of the wrist. The radius and ulna were secured in 2-inch aluminum pots using polymethylmethacrylate. Care was taken to ensure that the radius and ulna were fixed perpendicular to the horizontal axis of the pot. A metal tunnel was placed into the pot in line with the FPL tendon, allowing tendon sutures to be passed through. Kirschner wires were used to mimic a “pinch configuration” of the thumb by fixing the interphalangeal and metacarpophalangeal joints of the thumb at 15° of flexion and with the carpometacarpal joint in opposition. This position has been shown to generate a consistent load of 3 kg by the FPL tendon.<sup>2</sup> The wrist was fixed using a Schanz pin at 20° of extension.

The FPL tendon was transected at the musculotendinous junction, and No.2 Orthocord (DePuy Synthes, MiTek Sports Medicine) was attached to the proximal end of the tendon using a Krackow stitch to allow for the attachment of weights. The other flexor tendons and pronator quadratus muscle were reflected away from the radius to allow for direct placement of the sensor and volar plate (Fig. 1). Two eyelet screws



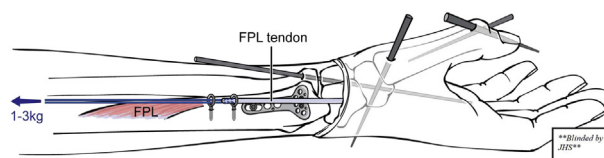
**FIGURE 1:** Experimental setup photograph.

were drilled into the radius in line with the FPL at the muscle belly centroid to restrict tendon bowstringing and ensure proper trajectory through the pot. This location was selected for each specimen as the midway point on the shaft of the radius in the direction and trajectory that the native FPL tendon ran. The tendon sutures were first passed through the eyelet screws and then through the tunnel in the pot to allow for weights to be attached during testing (Fig. 2).

Potted specimens were secured to the lab bench using a C-clamp. Finally, the FPL tendon was pre-tensioned by hanging 5 kg from the tendon sutures for 5 minutes to remove creep.

### Surgical conditions

Biomechanical testing was conducted using 1 kg and 3 kg in 5 surgical conditions for each specimen: “control,” “anatomic proximal,” “anatomic distal,” “dorsal proximal,” and “dorsal distal.” The first condition was the “control,” which measured contact pressure in an intact radius with no volar plate. Following pressure recordings of the control condition, the reproducible distal radius fracture was created. The fracture was created using a custom 3D



**FIGURE 2:** Experimental setup illustration.

printed osteotomy guide (TriMed) designed to fit proximal to the Lister tubercle on the dorsal side of the distal radius (Fig. 3). Using a sagittal saw, this guide allowed for a dorsal closing wedge osteotomy to be performed allowing for easy angulation and manipulation of the distal fragment.

After the osteotomy, the remaining 4 conditions were defined by volar plate fixation with differing combinations of plate position and volar tilt. The order of these 4 conditions was randomized. The “anatomic proximal” condition was defined as fixation with a volar plate placed just proximal to the watershed line, with complete restoration of the anatomic volar tilt (i.e., no dorsal angulation). The “anatomic distal” condition consisted of the same fixation and restoration of volar tilt; however, the plate was placed 2 mm distal to the watershed line. The “dorsal proximal” condition consisted of volar plate fixation placed just proximal to the watershed line with 10° of dorsal angulation in the distal fragment of the radius. This condition is approximately 20° from the anatomic distal radius, which is 11° of volar tilt as selected based on the fixed angle of the volar plate used in this study. Finally, the “dorsal distal” condition was defined as fixation with the volar plate placed 2 mm distal to the watershed line in addition to 10° of dorsal angulation in the distal fragment of the radius (Fig. 4).

For fracture fixation, a volar locking plate (TriMed Volar Variable Angle Plate; Volar Bearing Plate system, TriMed) was used. Volar plates were secured by placing 2 locking pegs in the central distal row holes. The proximal portion of the plate was secured with a screw placed in the oblong position allowing for the plate to be moved just proximal or 2 mm distal to the watershed line, depending on the condition being assessed. The level of volar tilt was confirmed with lateral radiographs for each condition using a PathVision Machine (Faxitron).

### Mechanical testing

For each surgical condition, weights of 1 kg and 3 kg were suspended from the FPL tendon sutures and allowed to stabilize for 1 minute before the pressure readings were recorded. Contact pressure measurements




FIGURE 3: Osteotomy guide.

were performed 3 times for each condition, and the average pressure measurement for each condition was used for analysis.

The contact force was measured with a small force transducer (FlexiForce ELF Measurement Sensor) placed between the FPL and the volar lip of the volar plate. This sensor measures and records pressure data in real-time. The contact force on the FPL tendon was measured just proximal to the watershed line of the distal radius.

### Statistical analysis

In the Tanaka et al<sup>21</sup> study, they observed an average effect size of 1.67 in the increase in pressure. Accepting that the forces would be the same as those studied in our investigation, the effect size showed that we would need 6 specimens to detect differences in plate contact between groups at an  $\alpha$  value of 0.05 and a power of 0.80. A 2-way analysis of variance was conducted to assess if differences between surgical conditions and applied load were statistically significant. Comparisons between surgical conditions within each test weight and between each test weight were conducted via a 2-way ANOVA.

## RESULTS

### Testing with 1 kg load

At 1 kg of test load, comparisons between the control and anatomic proximal conditions demonstrated no significant difference (mean difference = 0.07 N;  $P > .99$ ). Significant differences were observed between the control and all other conditions. Significant increases in contact pressure were observed between the control and both distal plate placement conditions (anatomic distal and dorsal distal) with mean differences of 0.52 N ( $P < .05$ )

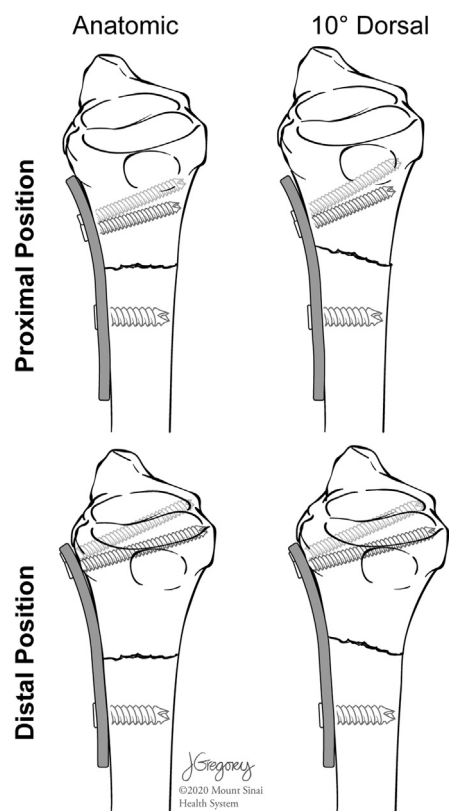


FIGURE 4: Testing conditions.

and 1.04 N ( $P < .05$ ), respectively. Furthermore, a significant increase was observed between the control and dorsal conditions with a mean of 0.71 N ( $P < .05$ ).

In comparison with the anatomic proximal condition, significant increases were observed in both dorsally angulated conditions (dorsal proximal and dorsal distal) with mean increases of 0.63 N ( $P < .05$ ) and 0.97 N ( $P < .05$ ), respectively. In

comparing the anatomic proximal and anatomic distal conditions, we found a contact pressure increase of 0.45 N ( $P = .07$ ), but this was not statistically significant.

A significant increase in contact pressure was observed between the anatomic distal and the dorsal distal conditions, with a mean increase of 0.53 N ( $P < .05$ ). No significant increase was observed in the comparisons between the dorsal condition and both the anatomic distal and dorsal distal conditions, with mean differences of 0.19 N ( $P = .93$ ) and 0.34 N ( $P = .31$ ), respectively.

### Testing with 3 kg load

At 3 kg of test weight, comparisons between the control and anatomic proximal conditions demonstrated no significant difference (mean difference = 0.11 N;  $P = .99$ ). Significant differences were observed in comparisons made between all other conditions.

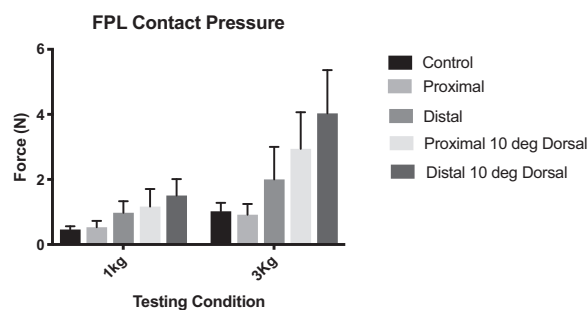
A significant increase was observed between the control and anatomic distal conditions with a mean of 0.98 N ( $P < .05$ ). Significant increases in contact pressure were also observed between the control and both dorsally angulated conditions (dorsal and dorsal distal) with mean increases of 1.9 N ( $P < .05$ ) and 3.0 N ( $P < .05$ ), respectively.

Compared with the anatomic proximal condition, significant increases were observed among all other conditions. A significant increase in contact force was observed between the anatomic proximal and the anatomic distal conditions with a mean difference of 1.09 N ( $P < .05$ ). Significant increases were also observed between the anatomic proximal condition and both the dorsal proximal and dorsal distal conditions, with mean differences of 2.03 N ( $P < .05$ ) and 3.12 N ( $P < .05$ ), respectively.

A significant increase in contact force between the anatomic distal and dorsal distal conditions was observed with a mean increase of 2.03 N ( $P < .05$ ). Significant increases in contact pressure were also observed between the dorsal proximal condition and both anatomic distal and dorsal distal conditions, with mean differences of 0.94 N ( $P < .05$ ) and 1.09 N ( $P < .05$ ), respectively (Fig. 5).

## DISCUSSION

Our study investigated the biomechanical effects of the loss of volar tilt and its effect on FPL tendon pressure. We also studied the impact of placing a volar plate distal to the watershed line in addition to the loss of volar tilt on FPL tendon pressure. A study by Wurtzel et al<sup>23</sup> showed that loss of volar tilt, plate position distal to the watershed line, and wrist



**FIGURE 5:** Flexor pollicis longus tendon contact pressures in testing conditions. Error bars represent 1 SD from the mean.

extension cause increased FPL tendon pressure. The investigation by Wurtzel et al<sup>23</sup> used a copper wire to create a circuit and measure electrical resistance.

Our results were consistent with Wurtzel et al,<sup>23</sup> confirming that plate position distal to the watershed line and loss of volar tilt increases pressure on the FPL tendon at 1 kg and 3 kg loads. Furthermore, our results confirmed our hypothesis that if the volar plate was placed proximal to the watershed line and the distal radius volar tilt was fixed anatomically, there was no increase in pressure on the FPL tendon compared with a control condition, which is comprised of no fracture and no volar plate. While the increase of contact pressure between the anatomic proximal and anatomic distal positions was not statistically significant, this may indicate that at the 1 kg force level, the sample size was insufficient to demonstrate the actual increase in pressure. This would be supported by the statistically significant increase observed at 3 kg.

Our results also indicate that failure to adequately restore volar tilt in the distal radius fragment leads to increased contact pressure on the FPL tendon and, thus, a potentially increased risk of tendon rupture. Therefore, care should be taken to completely restore anatomic volar tilt when reducing these fractures, whether by open reduction and internal fixation or closed reduction. Regarding how the angulation of the distal fragment plays into plate placement, our findings serve to further reinforce what was described by Orbay and Touhami.<sup>20</sup> If a plate is placed proximal to the watershed line, the FPL tendon will not be subject to any increased pressure if the normal anatomical alignment of the distal radius is restored. The gliding surface of the flexor tendons will not contact the volar plate if the implant does not cross or project volar to this distal ridge.

Previous reports have shown FPL tendon rupture rate to be as high as 12%.<sup>24</sup> FPL tendon rupture after open reduction and internal fixation is likely

multifactorial. Because of recent awareness of this complication, the importance of plate positioning, and the advent of low-profile volar plates, new studies suggest that the incidence of FPL tendon rupture may be decreasing.<sup>25,26</sup> While the incidence of rupture may be decreasing, the incidence of FPL tenosynovitis, which is likely a precursor to rupture, was reported to be as high as 21% in a series of 522 patients.<sup>25</sup> Hardware was removed in these symptomatic patients, perhaps preventing FPL tendon rupture.

In a series from Japan based on 2,787 patients,<sup>26</sup> the tendon rupture rate was as low as 0.35% (10/2,787). Half of the surgeons reported removing the implant in nearly all of their cases, which may lead to a decrease in FPL tendon rupture. In Japan, patients are covered by national health insurance, and therefore it was suggested in the report that most surgeons there would rather remove the implant than risk tendon rupture. In the United States, the cost of hardware removal must be considered, and implants are not typically removed if patients are asymptomatic. Clinically, our observation is that anatomic palmar tilt is somewhat difficult to achieve during surgery. The fracture is frequently fixed in a more neutral position, which results in nonphysiologically high pressure on the tendons that may be problematic.

There are several limitations to this study. The pronator quadratus was not repaired over the volar plate in this study to allow for accurate pressure sensor measurement. Ultrasound studies show that the distance between the FPL and volar prominence of the plate is increased with pronator quadratus repair, potentially decreasing the risk for FPL tendon rupture.<sup>27,28</sup> Furthermore, we removed soft tissues surrounding the FPL tendon such as the palmaris longus, flexor digitorum superficialis, flexor digitorum profundus, and flexor carpi radialis to prevent false-positive contact pressure. Removing these structures may alter the trajectory of the FPL tendon and may change pressure measurements despite our efforts to maintain the tendon at the anatomic position during testing. Therefore, our results could be different from those found *in vivo*. Furthermore, the sensor may have caused spurious pressure readings because of its placement between the FPL tendon and plate. Its thickness is 0.2 mm (0.008 in). We used this sensor because of its thin, flexible, and noninvasive nature; however, it does take up space that otherwise would not be an area of contact between the plate and tendon. Lastly, distal radius fractures are often reduced to a neutral position rather than anatomic or with dorsal alignment; therefore, it may have been

helpful to include another testing group with this condition.

In conclusion, our investigation suggests that both the failure to restore volar tilt and placement of a volar plate distal to the watershed line cause significant increases in pressure on the FPL tendon independently. This may be because of the leading edge of the plate causing increased pressure on the FPL tendon. This could potentially lead to complications such as FPL tenosynovitis and rupture. While surgeons realize an anatomic reduction is the desired outcome, we believe that suboptimal reductions, including a neutral or dorsal tilt, are sometimes accepted. This may lead to an increased risk of tendon rupture. Thus, careful attention must be paid to obtaining an anatomic volar tilt of the distal radius. We believe this is an essential component of fixation and may be as critical as obtaining proper plate placement proximal to the watershed line.

## ACKNOWLEDGMENTS

This study was completed through financial support from a 2017 AFSH, United States Fast Track Basic Science Grant and a donation by TriMed (Santa Clarita, CA) in the form of plates and screws.

## REFERENCES

1. Pogue DJ, Viegas SF, Patterson RM, et al. Effects of distal radius fracture malunion on wrist joint mechanics. *J Hand Surg Am.* 1990;15(5):721–727.
2. Baron JA, Karagas M, Barrett J, et al. Basic epidemiology of fractures of the upper and lower limb among Americans over 65 years of age. *Epidemiology.* 1996;7(6):612–618.
3. Shauver MJ, Yin H, Banerjee M, Chung KC. Current and future national costs to medicare for the treatment of distal radius fracture in the elderly. *J Hand Surg Am.* 2011;36(8):1282–1287.
4. Chung KC, Spilson SV. The frequency and epidemiology of hand and forearm fractures in the United States. *J Hand Surg Am.* 2001;26(5):908–915.
5. Ilyas AM. Surgical approaches to the distal radius. *Hand (N Y).* 2011;6(1):8–17.
6. Smith DW, Henry MH. Volar fixed-angle plating of the distal radius. *J Am Acad Orthop Surg.* 2005;13(1):28–36.
7. Orbay JL, Fernandez DL. Volar fixation for dorsally displaced fractures of the distal radius: a preliminary report. *J Hand Surg Am.* 2002;27(2):205–215.
8. Kamano M, Honda Y, Kazuki K, Yasuda M. Palmar plating for dorsally displaced fractures of the distal radius. *Clin Orthop Relat Res.* 2002;397(397):403–408.
9. Koval KJ, Harrast JJ, Anglen JO, Weinstein JN. Fractures of the distal part of the radius. The evolution of practice over time. Where's the evidence? *J Bone Joint Surg Am.* 2008;90(9):1855–1861.
10. Azzi AJ, Aldekhayel S, Boehm KS, Zadeh T. Tendon rupture and tenosynovitis following internal fixation of distal radius fractures: a systematic review. *Plast Reconstr Surg.* 2017;139(3):717e–724e.
11. Ruch DS, Papadonikolakis A. Volar versus dorsal plating in the management of intra-articular distal radius fractures. *J Hand Surg Am.* 2006;31(1):9–16.

12. Osada D, Viegas SF, Shah MA, Morris RP, Patterson RM. Comparison of different distal radius dorsal and volar fracture fixation plates: a biomechanical study. *J Hand Surg Am.* 2003;28(1):94–104.
13. Loisel F, Kielwasser H, Faivre G, et al. Treatment of distal radius fractures with locking plates: an update. *Eur J Orthop Surg Traumatol.* 2018;28(8):1537–1542.
14. Bell JS, Wollstein R, Citron ND. Rupture of flexor pollicis longus tendon: a complication of volar plating of the distal radius. *J Bone Joint Surg Br.* 1998;80(2):225–226.
15. Al-Rashid M, Theivendran K, Craigen MAC. Delayed ruptures of the extensor tendon secondary to the use of volar locking compression plates for distal radial fractures. *J Bone Joint Surg Br.* 2006;88(12):1610–1612.
16. Casaletto JA, Machin D, Leung R, Brown DJ. Flexor pollicis longus tendon ruptures after palmar plate fixation of fractures of the distal radius. *J Hand Surg Eur Vol.* 2009;34(4):471–474.
17. Adham MN, Porembski M, Adham C. Flexor tendon problems after volar plate fixation of distal radius fractures. *Hand (N Y).* 2009;4(4):406–409.
18. Soong M, Earp BE, Bishop G, Leung A, Blazar P. Volar locking plate implant prominence and flexor tendon rupture. *J Bone Joint Surg Am.* 2011;93(4):328–335.
19. Satake H, Hanaka N, Honma R, et al. Complications of distal radius fractures treated by volar locking plate fixation. *Orthopedics.* 2016;39(5):e893–e896.
20. Orbay JL, Touhami A. Current concepts in volar fixed-angle fixation of unstable distal radius fractures. *Clin Orthop Relat Res.* 2006;445:58–67.
21. Tanaka Y, Aoki M, Izumi T, Fujimiya M, Yamashita T, Imai T. Effect of distal radius volar plate position on contact pressure between the flexor pollicis longus tendon and the distal plate edge. *J Hand Surg Am.* 2011;36(11):1790–1797.
22. Asadollahi S, Keith PPA. Flexor tendon injuries following plate fixation of distal radius fractures: a systematic review of the literature. *J Orthop Traumatol.* 2013;14(4):227–234.
23. Wurtzel CNW, Burns GT, Zhu AF, Ozer K. Effects of volar tilt, wrist extension, and plate position on contact between flexor pollicis longus tendon and volar plate. *J Hand Surg Am.* 2017;42(12):996–1001.
24. Drobetz H, Kutscha-Lissberg E. Osteosynthesis of distal radial fractures with a volar locking screw plate system. *Int Orthop.* 2003;27(1):1–6.
25. Cook A, Baldwin P, Fowler JR. Incidence of flexor pollicis longus complications following volar locking plate fixation of distal radius fractures. *Hand (N Y).* 2020;15(5):692–697.
26. Sato K, Murakami K, Mimata Y, Doita M. Incidence of tendon rupture following volar plate fixation of distal radius fractures: a survey of 2787 cases. *J Orthop.* 2018;15(1):236–238.
27. Goorens CK, Van Royen K, Grijseels S, Probyn S, De Mey J, Scheerlinck T, Goubau JF. Ultrasonographic evaluation of the distance between the flexor pollicis longus tendon and volar prominence of the plate as a function of volar plate positioning and pronator quadratus repair – a cadaver study. *Hand Surg Rehabil.* 2018;37(3):171–174.
28. Walch A, Erhard L, Vogels J, Pozzetto M, Gibert N, Locquet V. Ultrasound evaluation of the protector role of the pronator quadratus suture in volar plating. *J Ultrasound Med.* 2019;38(10):2785–2791.