

Risk of Infection in Trigger Finger Release Surgery Following Corticosteroid Injection

Jonas L. Matzon, MD,* Cory Lebowitz, DO,* Jack G. Graham, BS,* Ludovico Lucenti, MD,*
Kevin F. Lutsky, MD,* Pedro K. Beredjikian, MD*

Purpose To determine the risk for infection in trigger finger release surgery after preoperative corticosteroid injection.

Methods We retrospectively evaluated all patients undergoing trigger finger release by 16 surgeons over a 2-year period. Data collected included demographic information, medical comorbidities, trigger finger(s) operated on, presence of a prior corticosteroid injection, date of most recent corticosteroid injection, postoperative signs of infection, and need for surgery owing to deep infection. Superficial infection was defined per Centers for Disease Control criteria. Deep infection was defined as the need for surgery related to a surgical site infection.

Results In this cohort of 2,480 fingers in 1,857 patients undergoing trigger release surgery, 53 (2.1%) developed an infection (41 superficial [1.7%] and 12 deep [0.5%]). Before surgery, 1,137 fingers had no corticosteroid injection. These patients developed 1 deep (0.1%) and 17 superficial (1.5%) infections. In contrast, 1,343 fingers had been given a corticosteroid injection before surgery. These patients developed 11 deep (0.8%) and 24 superficial (1.8%) infections. Median time from corticosteroid injection to trigger release surgery was shorter for fingers that developed a deep infection (63 days) compared with those that developed no infection (183 days). The risk for developing a deep infection in patients who were operated on within 90 days of an injection (8 infections in 395 fingers) was increased compared with patients who were operated on greater than 90 days after an injection (3 infections in 948 fingers).

Conclusions Preoperative corticosteroid injections are associated with a small but statistically significantly increased rate of deep infection after trigger finger release surgery. The risk for postoperative deep infection seems to be time dependent and greater when injections are performed within 90 days of surgery, especially in the 31- to 90-day postinjection period. (*J Hand Surg Am.* 2020;45(4):310–316. Copyright © 2020 by the American Society for Surgery of the Hand. All rights reserved.)

Type of study/level of evidence Therapeutic IV.

Key words Corticosteroid injection, infection, risk factors, stenosing tenosynovitis, trigger finger release.

From *Rothman Orthopaedic Institute, Thomas Jefferson University, Philadelphia, PA.

Received for publication April 5, 2019; accepted in revised form January 10, 2020.

No benefits in any form have been received or will be received related directly or indirectly to the subject of this article.

Corresponding author: Jonas L. Matzon, MD, Rothman Orthopaedic Institute, Thomas Jefferson University, 925 Chestnut Street, 5th Floor, Philadelphia, PA 19107; e-mail: jonas.matzon@rothmanortho.com.

0363-5023/20/4504-0005\$36.00/0
<https://doi.org/10.1016/j.jhssa.2020.01.007>

TRIGGER FINGER OR STENOSING flexor tenosynovitis of the A1 pulley is a commonly encountered condition in the adult population, with an estimated lifetime prevalence of 2%.¹ Corticosteroid injections are the mainstay of nonsurgical treatment and have a reported success rate between 40% and 90%.^{2–4} Theoretical risks of injection include flare reaction, tendon rupture, local infection, blood glucose elevation, and fat atrophy,

but limited data exist on these complications.^{5–7} Given this risk–benefit profile, corticosteroid injections are often recommended before surgery.^{8,9} Although repeat injections have demonstrated some benefit, they seem to be less effective than initial injections.¹⁰

The effect of corticosteroid injections on subsequent trigger finger release surgery is poorly understood. Specifically, it is unknown whether corticosteroid injections increase the risk for postoperative complications, such as impaired wound healing and surgical site infection. At other body locations, corticosteroid injections before surgery have demonstrated occasional detrimental postoperative effects. For example, injections before total knee and hip arthroplasty have been associated with a higher risk for postoperative infection.^{11–14} In general, the risk for adverse events after trigger finger release surgery is low, but deep infection consistent with suppurative flexor tenosynovitis has been reported.^{15,16}

The purpose of our study was to evaluate the association of corticosteroid injections and infection rate after subsequent trigger finger release surgery. Our hypothesis was that corticosteroid injections would be associated with an increased risk for infection and that the risk would be time dependent with injections closer to surgery carrying greater risk.

MATERIALS AND METHODS

Institutional review board approval was obtained and informed consent was waived per our institutional protocol. We performed a retrospective review of patients undergoing trigger finger release surgery at our institution over a 2-year period (January 1, 2016 to January 1, 2018). Our surgical database was queried for patients based on Current Procedural Terminology code 26055 (tendon sheath incision, eg, for trigger finger). Sixteen board-certified orthopedic hand surgeons performed the procedures.

We reviewed the electronic medical record of all patients captured by the query. Data collected included demographic information, medical comorbidities (diabetes mellitus, anxiety, depression, alcohol use, and tobacco history), operative trigger finger(s), presence or absence of prior corticosteroid injections to the flexor sheath, the date of the most recent corticosteroid injection to the operative finger, postoperative signs of infection (erythema, swelling, warmth, pain, and/or purulence), and the need for postoperative surgery owing to deep infection of the involved finger. Superficial infection was defined as

per the Centers for Disease Control and Preventions (CDC) criteria of a superficial surgical site infection (Fig. 1).¹⁷ Deep infection was defined as the need for surgical irrigation and debridement related to a surgical site infection, with confirmation of deep infection at the time of surgery. All patients who underwent any trigger finger release were included in the study, irrespective of whether their release was isolated or performed in combination with another hand surgical procedure. Patients were excluded if they had missing preoperative documentation with respect to corticosteroid injection.

The individual surgeons determined the type and quantity of corticosteroid used and the frequency of injections before surgery. Indications for trigger finger release were symptoms refractory to nonsurgical treatment. The surgical technique, type of wound closure, use of perioperative antibiotics, duration of dressing, use of postoperative antibiotics, and need for a secondary surgery were based on the discretion of the treating surgeon.

We performed statistical analysis using Fisher exact and chi-square tests for categorical variables and Student *t* test for continuous variables. Odds ratios with corresponding 95% confidence intervals (CIs) were used to compare the incidence of postoperative infection. Odds ratios were calculated for the infection end points for the 2 cohorts as a whole and for each interval of the subgroup analysis. Statistical significance was set at $P < .05$.

RESULTS

A total of 2,928 fingers in 2,230 patients underwent trigger release during the study period. We excluded 448 fingers based on incomplete preoperative documentation with respect to injection, which resulted in a cohort of 2,480 trigger fingers in 1,857 patients. Before being released, 1,137 fingers (46%) had no corticosteroid injections (injection-no), whereas 1,343 fingers (54%) had corticosteroid injections (injection-yes) (Fig. 2). Demographics and medical comorbidities were similar for fingers treated with and without injections (Table 1).

Overall, 53 fingers (2.1%) developed a surgical site infection: 41 (1.7%) superficial and 12 (0.5%) deep. Average time from trigger finger release and subsequent surgical irrigation and debridement was 25 days (range, 9–49 days). Intraoperative cultures were positive in 8 patients (5 *Staphylococcus aureus*, 2 coagulase-negative *Staphylococcus*, and 1 *Pseudomonas aeruginosa*), negative in 2, and unavailable in 2. All 4 patients with negative or unavailable

Inclusion Criteria	Exclusion Criteria
<p>Infection occurs within 30 days after the operation <i>and</i> infection involves only skin or subcutaneous tissue of the incision <i>and</i> at least 1 of the following:</p> <ol style="list-style-type: none"> 1. Purulent drainage, with or without laboratory confirmation, from the superficial incision 2. Organism isolated from an aseptically obtained culture of fluid or tissue from the superficial incision 3. At least 1 of the following signs or symptoms of infection: pain or tenderness, localized swelling, redness, or heat; also, superficial incision is deliberately opened by the surgeon, unless incision is culture negative 4. Diagnosis of superficial incisional SSI by the surgeon or attending physician 	<p>Do <i>not</i> report the following conditions as SSI:</p> <ol style="list-style-type: none"> 1. Stitch abscess (minimal inflammation and discharge confined to the points of suture penetration) 2. Infection of an episiotomy or newborn circumcision site 3. Infected burn wound 4. Incision SSI that extends into the fascial and muscle layers (deep incisional SSI)

FIGURE 1: Centers for Disease Control and Preventions criteria of a superficial surgical site (SSI) infection.

cultures had preoperative signs of infection including purulent wound drainage and had been taking antibiotics before operative debridement. Of the 1,137 injection-no fingers, 17 (1.5%) developed a superficial infection and 1 (0.1%) developed a deep infection. Of the 1,343 injection-yes fingers, 24 (1.8%) developed a superficial infection and 11 (0.8%) developed a deep infection. The odds ratio of developing a superficial infection for patients in the injection-yes group was 1.19 (95% CI, 0.64–2.24) compared with patients in the injection-no group ($P = .57$), which was not statistically significant. The odds ratio of developing a deep infection for patients in the injection-yes group was 9.38 (95% CI, 1.21–72.78) compared with patients in the injection-no group ($P < .05$), which suggests an association. Of the 448 patients who were excluded, none developed a deep infection.

For the injection-yes fingers, median time from corticosteroid injection to trigger finger release surgery was 181 days (range, 6–869 days). Median time from injection to surgery was shorter for fingers that developed a deep infection (63 days [range, 37–176 days]) compared with fingers that developed no infection (183 days [range, 6–869 days]) and those that developed a superficial infection (203 days [range, 15–569 days]).

Table 2 shows the number of deep infections in relation to the time from injection to surgery. The odds ratio of developing a deep infection in patients who were operated on within 90 days (8 infections in 395 fingers) of an injection was 6.51 (95% CI,

1.71–24.67) compared with patients who were operated on greater than 90 days after an injection (3 infections in 948 fingers; $P < .05$). This difference suggests an association between the time interval between injection and surgery and the development of deep infection.

When broken down into 30-day increments, there were no infections in patients operated on within 30 days or after 180 days of the injection. However, the odds ratio of developing a deep infection when operated on between 31 and 60 days after the injection was 35.4 (95% CI, 4.1–304.9) compared with the injection-no group ($P < .05$). Similarly, the odds ratio of developing a deep infection when operated on between 61 and 90 days after the injection was 28.7 (95% CI, 2.97–278.2) compared with the injection-no group ($P < .05$). These differences again suggest an association between the time interval between injection and surgery and the development of deep infection. For all other 30-day intervals beyond the 90-day time point of injection, the differences in odd ratios between the injection-yes and the injection-no groups were not statistically significant ($P > .05$).

DISCUSSION

Corticosteroids are typically used as the first-line treatment for trigger fingers.^{8,9} Their anti-inflammatory properties are beneficial in the treatment of this condition, but they are also immunosuppressive and can increase the risk for infection.¹⁸ In the joint arthroplasty literature, corticosteroid

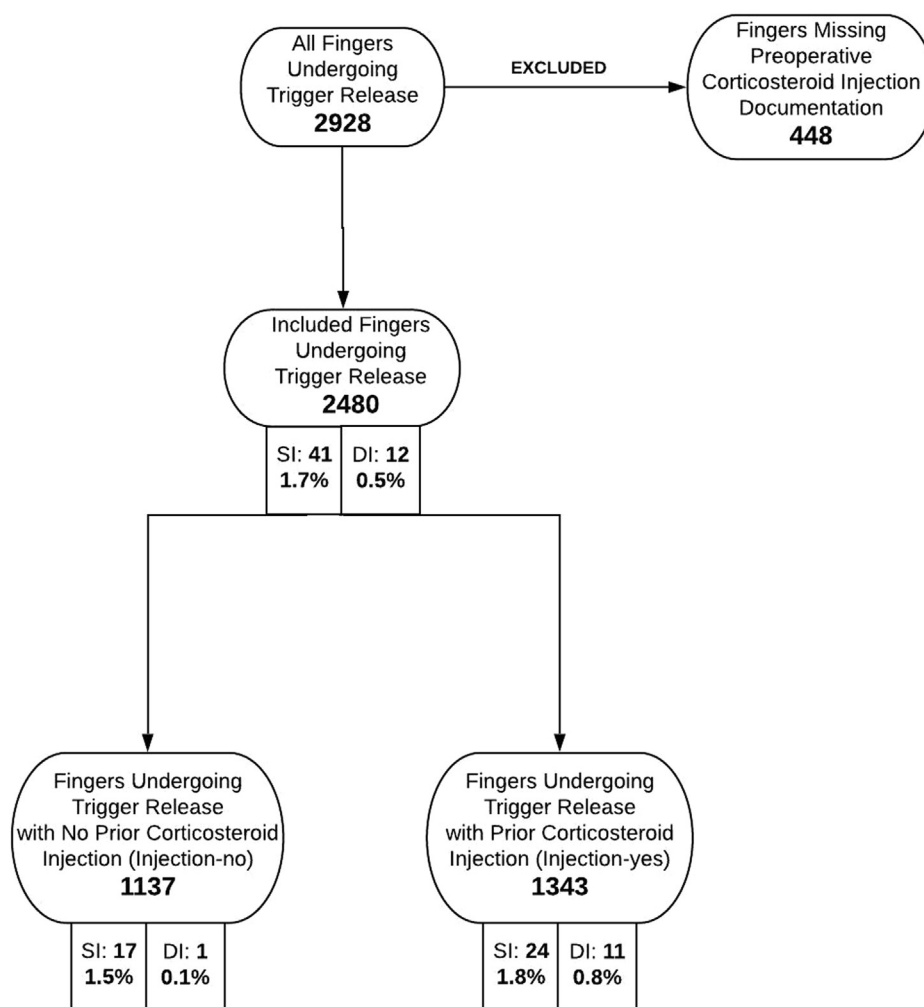


FIGURE 2: Flowchart depicting patient cohorts. DI, deep infection; SI, superficial infection.

injections have been shown to increase infection rates when performed less than 3 months before surgery.^{11–14} For this reason, many joint surgeons are reluctant to perform total joint replacement in patients who have had recent injections. We identified an increased risk for deep infection in patients undergoing trigger finger surgery after injection, and in concordance with the total joint literature, we found that this risk was particularly elevated when surgery was performed less than 3 months after injection. This relation between corticosteroid injection and subsequent deep surgical site infection is an important consideration when discussing risks and benefits of both nonsurgical and operative treatment of stenosing tenosynovitis. In general, the benefits of providing a corticosteroid injection to a patient with this condition, and potentially avoiding surgery, likely outweigh the risks. However, in patients for whom the injection provides minimal or short-lived

symptom improvement, delaying surgery until after 3 months after injection may be prudent.

Two other studies evaluated this relation in trigger finger patients, with conflicting findings. In a retrospective review of 795 fingers undergoing trigger release, Everding et al¹⁹ found no association between recent corticosteroid injection (<1 month, 1–3 months, and >3 months) and complications such as infection. In their study, 8 fingers (1.0%) required oral antibiotics for superficial infection and 4 fingers (0.5%) required return to the operating room for irrigation and debridement of deep infection. These authors did not clearly document the timing of the preoperative corticosteroid injection with respect to surgery. It is possible that their patients underwent surgical release at later time points than did our patients.

In a more recent retrospective study of 999 trigger releases, Ng et al²⁰ identified corticosteroid injection

TABLE 1. Patient Demographics and Medical Comorbidities

	No Corticosteroid Injections (Injection-No)	Corticosteroid Injections (Injection-Yes)
Fingers, n	1,137	1,343
Mean age, y	64	64
Females (%)	62	58
Diabetes (%)	19	26
Depression/ anxiety (%)	12	13
Alcohol use (%)	46	51
Tobacco use (%)	13	13

timing relative to subsequent operative intervention as a risk factor for postoperative surgical site infection. Of 780 patients, 26 (3.3%) had a postoperative infection. Patients who had previously received an injection were significantly more likely to have an infection (5.5% vs 1.6%), and patients who had an injection and then became infected had a significantly shorter interval between injection and surgery (79 vs 260 days). Unlike our study, Ng et al defined postoperative infection broadly as any mention of “infection” in the chart including suture abscess and any surgical site that required antibiotics. Furthermore, the authors did not distinguish between deep and superficial infections. Both of these factors may have resulted in an overestimation of the infection rate and a mischaracterization of infection severity. They also noted a substantially higher infection rate (9.8%) at one facility (the authors theorize that this group of patients may have another, as yet unidentified, source of higher rate of infection) that may have contributed spuriously to their findings. In contrast, we used the CDC criteria to identify superficial surgical site infections and defined deep infection as a return to the operating room for an irrigation and debridement. Furthermore, we evaluated infections by monthly and 3-month intervals to understand better when the risk for a corticosteroid injection starts to dissipate. Based on our findings, this seems to occur after 3 months.

In our study, the risk for postoperative infection seems to be time dependent, in which closer proximity between injection and trigger finger release is associated with a higher risk for infection. Most of the deep infections occurred when injections were

TABLE 2. Deep Infections per Injection Interval

Injection Interval, d	Total	DI	% DI	% DI/3 mo
0–30	69	0	0.0	
31–60	190	5	2.6	2.0
61–90	136	3	2.2	
91–120	100	1	1.0	
121–150	98	1	1.0	1.1
151–180	76	1	1.3	
181–210	87	0	0.0	
211–240	95	0	0.0	0.0
241–270	74	0	0.0	
271–300	57	0	0.0	
301–330	79	0	0.0	0.0
331–360	66	0	0.0	
> 360	216	0	0.0	
Total	1,343	11	0.8	

performed within 90 days of surgery; however, infections also occurred when performed between 91 and 180 days of surgery. This is similar to findings in the arthroplasty literature.¹¹

The exact mechanism by which a previous corticosteroid injection may increase the risk for surgical site infection is unclear. In general, corticosteroids interrupt the inflammatory and immune cascade at several levels.²¹ Consequently, corticosteroids can impair wound healing by delaying the delivery of inflammatory cells, fibroblasts, vascular ingrowth, collagen deposition, and epithelial migration.²² However, the wound-healing process is complex. The proliferative and remodeling stages of healing (which occur 3 to 4 weeks after injury or surgery) display biologic modulator and cytokine profiles completely different from those observed in the immediate postinjury or operative period. For example, transforming growth factor- β 1, a potent proinflammatory cytokine, does not become fully active until the proliferative stage, and corticosteroids are known to inhibit transforming growth factor- β 1 production.²³ Therefore, it is conceivable that the corticosteroid effects influencing the modulators in the later stages of healing would not manifest immediately. As such, that we observed no infections in the first month after surgery does not necessarily conflict with our hypothesis of a time-dependent relation between the administration of locally injected corticosteroid and surgical site infection risk.

Although corticosteroids are immunosuppressive, they are often given during surgery in other systemic

forms without obvious side effects. For example, among patients who underwent surgical fixation of terrible triad elbow injuries, Desai et al²⁴ reported improved range of motion but no change in complication rate with the administration of a single intraoperative dose of 10 mg intravenous dexamethasone followed by a 6-day oral methylprednisolone taper. Similarly, among patients who underwent total hip and knee arthroplasty, Richardson et al²⁵ found no increase in the incidence of infection for patients receiving a single intravenous dose (4–10 mg) of dexamethasone for prophylaxis against postoperative nausea and vomiting. It would seem rational that the infection risk for perioperative corticosteroids is correlated to the location and route of administration in relation to the surgical site. However, the half-life for most common injectable steroids is less than 7 days.¹⁸ Counterintuitively, we had no infections when injections were performed from 0 to 30 days before surgery (the shortest interval), followed by an increase when injections were performed from 31 to 90 days before surgery. More research is necessary to better understand the relation between injection and postoperative trigger finger infections.

This study had several strengths. First, compared with the existing literature, it was a relatively large study with 2,480 trigger fingers included. Second, in contrast to database studies, all charts were reviewed, so there was less dependence on proper coding for accurate data collection.

This study also had several limitations. Most of these limitations are based on the study's retrospective design. First, treatment protocols were not standardized. Although surgeons in our practice typically offer at least one corticosteroid injection before trigger finger release surgery, a substantial number of patients did not receive an injection before surgery. In general, these patients had previously failed corticosteroid injections for other trigger fingers and opted to forgo injection, had the trigger finger released in association with another concomitant procedure (carpal tunnel release, basal joint arthroplasty, etc), had a relative contraindication to corticosteroids, or simply refused an injection. Overall, the number and timing of corticosteroid injections, indications for surgery, administration of preoperative antibiotics, operative technique, and postoperative protocols were all at the discretion of the attending surgeon. Although it is possible that any one of these factors could have had an impact on the risk for infection, we think this reflects normal variation in clinical practice and serves to improve the generalizability of our results. Second, given the retrospective nature of this study, fingers

were not randomized to receive or not receive an injection. Although the demographics and medical comorbidities were similar for fingers treated with and without injections, it is possible that some unidentified confounder had an impact on the occurrence of infection. Third, the diagnosis of infection can be subjective, and identification of these patients depends on adequate documentation in the chart. We attempted to minimize subjectivity by using CDC criteria for superficial infection and the need for surgical irrigation and debridement as criteria for deep infection. However, because of inconsistent and/or incomplete documentation in the medical record that is inherent in retrospective studies and the possibility that patients may have been treated elsewhere for an infection (and therefore not accounted for in our data analysis), it is possible that there may have been some inaccuracy in our infection rates. Fourth, we did not stratify patients based on whether they had trigger finger release in isolation or as part of another surgery. It is possible that the infection rate is influenced by whether a concomitant procedure is performed, or whether multiple trigger digits are released. Because most deep infections occurred in patients undergoing isolated trigger releases, we would not expect this to be a major factor. Fifth, we excluded 448 trigger fingers with missing preoperative documentation with respect to corticosteroid injection. Most of these patients had corticosteroid injections performed by physicians outside our practice; therefore, we could not verify the specific dates of injection. None of these patients developed a deep infection, and we thought that excluding these patients made our data more accurate. Sixth, we were unable to ascertain uniformly the specific type and dose of corticosteroid used in each injection. It is possible that there is a dose- or substance-dependent effect, which we were unable to identify. Finally, we could not determine the total number or timing of lifetime corticosteroid injections in a given finger, a parameter that may have some influence on the infection rate.

The effect of corticosteroid injections on subsequent trigger finger release surgery remains poorly understood. It is possible that factors other than the administration of preoperative corticosteroid injections have a role in the development of surgical site infection. We continue to recommend injection as a first line nonsurgical treatment for trigger fingers. However, based on the results of our study and the substantial morbidity of suppurative flexor tenosynovitis, we recommend avoiding trigger finger release surgery within 90 days of a corticosteroid injection and especially in the 31- to 90-day postinjection

period. We counsel patients that the risk for infection decreases the longer the time is from the injection. This may be a consideration in particular when discussing surgery with patients who had a short duration of success with previous corticosteroid injection.

REFERENCES

- Peters-Veluthamaningal C, van der Windt DAM, Winters JC, Meyboom-de Jong B. Corticosteroid injection for trigger finger in adults. *Cochrane Database Syst Rev*. 2009;1:CD005617.
- Dala-Ali BM, Nakhdjevani A, Lloyd MA, Schreuder FB. The efficacy of steroid injection in the treatment of trigger finger. *Clin Orthop Surg*. 2012;4(4):263–268.
- Rozental TD, Zurakowski D, Blazar PE. Trigger finger: prognostic indicators of recurrence following corticosteroid injection. *J Bone Joint Surg Am*. 2008;90(8):1665–1672.
- Fleisch SB, Spindler KP, Lee DH. Corticosteroid injections in the treatment of trigger finger: a level I and II systematic review. *J Am Acad Orthop Surg*. 2007;15(3):166–171.
- Goldfarb CA, Gelberman RH, McKeon K, Chia B, Boyer MI. Extra-articular steroid injection: early patient response and the incidence of flare reaction. *J Hand Surg Am*. 2007;32(10):1513–1520.
- Kim N, Schroeder J, Hoffler CE, Matzon JL, Lutsky KF, Beredjiklian PK. Elevated hemoglobin A1C levels correlate with blood glucose elevation in diabetic patients following local corticosteroid injection in the hand: a prospective study. *Plast Reconstr Surg*. 2015;136(4):474e–479e.
- Pace CS, Blanchet NP, Isaacs JE. Soft tissue atrophy related to corticosteroid injection: review of the literature and implications for hand surgeons. *J Hand Surg Am*. 2018;43(6):558–563.
- Kerrigan CL, Stanwix MG. Using evidence to minimize the cost of trigger finger care. *J Hand Surg Am*. 2009;34(6):997–1005.
- Halim A, Sobel AD, Eltorai AEM, Mansuripur KP, Weiss A-PC. Cost-effective management of stenosing tenosynovitis. *J Hand Surg Am*. 2018;43(12):1085–1091.
- Dardas AZ, VandenBerg J, Shen T, Gelberman RH, Calfee RP. Long-term effectiveness of repeat corticosteroid injections for trigger finger. *J Hand Surg Am*. 2017;42(4):227–235.
- Bedard NA, Pugely AJ, Elkins JM, et al. The John N. Insall Award: do intraarticular injections increase the risk of infection after TKA? *Clin Orthop Relat Res*. 2017;475(1):45–52.
- Cancienne JM, Werner BC, Luetkemeyer LM, Browne JA. Does timing of previous intra-articular steroid injection affect the post-operative rate of infection in total knee arthroplasty? *J Arthroplasty*. 2015;30(11):1879–1882.
- Werner BC, Cancienne JM, Browne JA. The timing of total hip arthroplasty after intraarticular hip injection affects postoperative infection risk. *J Arthroplasty*. 2016;31(4):820–823.
- Schairer WW, Nwachukwu BU, Mayman DJ, Lyman S, Jerabek SA. Preoperative hip injections increase the rate of periprosthetic infection after total hip arthroplasty. *J Arthroplasty*. 2016;31(9 suppl):166–169.e1.
- Bruijnzeel H, Neuhaus V, Fostvedt S, Jupiter JB, Mudgal CS, Ring DC. Adverse events of open A1 pulley release for idiopathic trigger finger. *J Hand Surg Am*. 2012;37(8):1650–1656.
- Ricci JA, Parekh NN, Desai NS. Release of the A1 pulley for trigger finger complicated by flexor tenosynovitis. *J Hand Microsurg*. 2015;7(1):220–223.
- Mangram AJ, Horan TC, Pearson ML, Silver LC, Jarvis WR. Guideline for prevention of surgical site infection, 1999. Centers for Disease Control and Prevention (CDC) Hospital Infection Control Practices Advisory Committee. *Am J Infect Control*. 1999;27(2):97–132; quiz 133–134; discussion 96.
- Dahl J, Hammert WC. Overview of injectable corticosteroids. *J Hand Surg Am*. 2012;37(8):1715–1717.
- Everding NG, Bishop GB, Belyea CM, Soong MC. Risk factors for complications of open trigger finger release. *Hand (N Y)*. 2014;10(2):297–300.
- Ng WKY, Olmscheid N, Worhacz K, Sietsema D, Edwards S. Steroid injection and open trigger finger release outcomes: a retrospective review of 999 digits [published online ahead of print September 21, 2018]. *Hand (N Y)*. <https://doi.org/10.1177/1558944718796559>.
- Ayhan E, Kesmezacar H, Akgun I. Intraarticular injections (corticosteroid, hyaluronic acid, platelet rich plasma) for the knee osteoarthritis. *World J Orthop*. 2014;5(3):351–361.
- Wicke C, Halliday B, Allen D, et al. Effects of steroids and retinoids on wound healing. *Arch Surg*. 2000;135(11):1265–1270.
- Wen FQ, Kohyama T, Sköld CM, et al. Glucocorticoids modulate TGF-beta production. *Inflammation*. 2002;26(6):279–290.
- Desai MJ, Matson AP, Ruch DS, Leversedge FJ, Aldridge JM, Richard MJ. Perioperative glucocorticoid administration improves elbow motion in terrible triad injuries. *J Hand Surg Am*. 2017;42(1):41–46.
- Richardson AB, Bala A, Wellman SS, Attarian DE, Bolognesi MP, Grant SA. Perioperative dexamethasone administration does not increase the incidence of postoperative infection in total hip and knee arthroplasty: a retrospective analysis. *J Arthroplasty*. 2016;31(8):1784–1787.