

REFERENCES

1. Cobb TK, Beckenbaugh RD. Biaxial long-stemmed multipronged distal components for revision/bone deficit total-wrist arthroplasty. *J Hand Surg Am.* 1996;21(5):764–770.
2. Ward CM, Kuhl T, Adams BD. Five to ten-year outcomes of the Universal total wrist arthroplasty in patients with rheumatoid arthritis. *J Bone Joint Surg Am.* 2011;93(10):914–919.
3. Ferreres A, Lluch A, Del Valle M. Universal total wrist arthroplasty: midterm follow-up study. *J Hand Surg Am.* 2011;36(6):967–973.
4. Harlingen Dv, Heesterbeek PJ, J de Vos M. High rate of complications and radiographic loosening of the biaxial total wrist arthroplasty in rheumatoid arthritis: 32 wrists followed for 6 (5–8) years. *Acta Orthop.* 2011;82(6):721–726.
5. Rettig ME, Beckenbaugh RD. Revision total wrist arthroplasty. *J Hand Surg Am.* 1993;18(5):798–804.

An Easy and Applicable Method for Stripping and Smoothing the Tendon Ends: Sterile Wooden Tongue Depressor

To the Editor:

During primary tendon repairs and tendon transfer operations, tendon ends have to be smooth and tidy to achieve optimum tendon healing. Although minimal handling is imperative, holding the tendon and trimming the ends are difficult because the epitendon and synovial fluid makes the tendon slippery. Multiple efforts to tidy the ends can cause further shortening and cause increased tension in the repair zone, which can lead to tendon repair rupture.¹ Tendon ends are also exposed to blunt trauma from being held with forceps in the course of these prolonged efforts, and

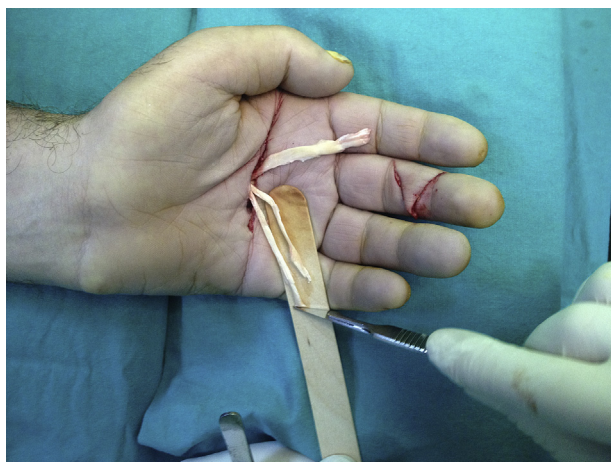


FIGURE 1: Stripping and smoothing the tendon ends over a sterile wooden tongue depressor during a flexor digitorum superficialis 4-tail procedure for correcting a claw hand deformity.

the epitenon injury can be associated with peritendinous adhesion formation.^{2,3}

To strip and smooth the tendon ends, we use an ethylene oxide–sterilized wooden tongue depressor. We lay the tendon ends on the tongue depressor to stabilize them, and can then easily cut the ends or strip along the tendon with a scalpel (Fig. 1). We prefer a dry wooden tongue depressor, and the scalpel direction proceeds with no deviation. We have not observed complications as the result of using a tongue depressor. We confidently recommend this technique to our colleagues as an effective, safe, cheap, and easily available method of smoothing and stripping the tendon ends.

Hakan Bulam, MD

Onur Öztürk, MD

Erkin Ünlü, MD

Department of Plastic Reconstructive and

Aesthetic Surgery

Ankara Numune Training and Research Hospital

Ankara, Turkey

<http://dx.doi.org/10.1016/j.jhsa.2013.12.018>

REFERENCES

1. Wu YF, Tang JB. Effects of tension across the tendon repair site on tendon gap and ultimate strength. *J Hand Surg Am.* 2012;37(5):906–912.
2. Seiler JG III. Flexor tendon injury: acute injury. In: Wolfe SW, ed. *Green's Operative Hand Surgery.* 6th ed. Philadelphia, PA: Elsevier; 2011:199–200.
3. Dy CJ, Hernandez-Soria A, Ma Y, Roberts TR, Daluiski A. Complications after flexor tendon repair: a systematic review and meta-analysis. *J Hand Surg Am.* 2012;37(3):543–551.

Posterior Interosseus Nerve Entrapment Following Monteggia Fracture Dislocation

To the Editor:

We recently treated a 27-year-old woman who sustained a closed left Bado type 1 Monteggia

fracture-dislocation during a fall. In the emergency department, the patient was noted to have a posterior interosseus nerve (PIN) palsy before and after closed